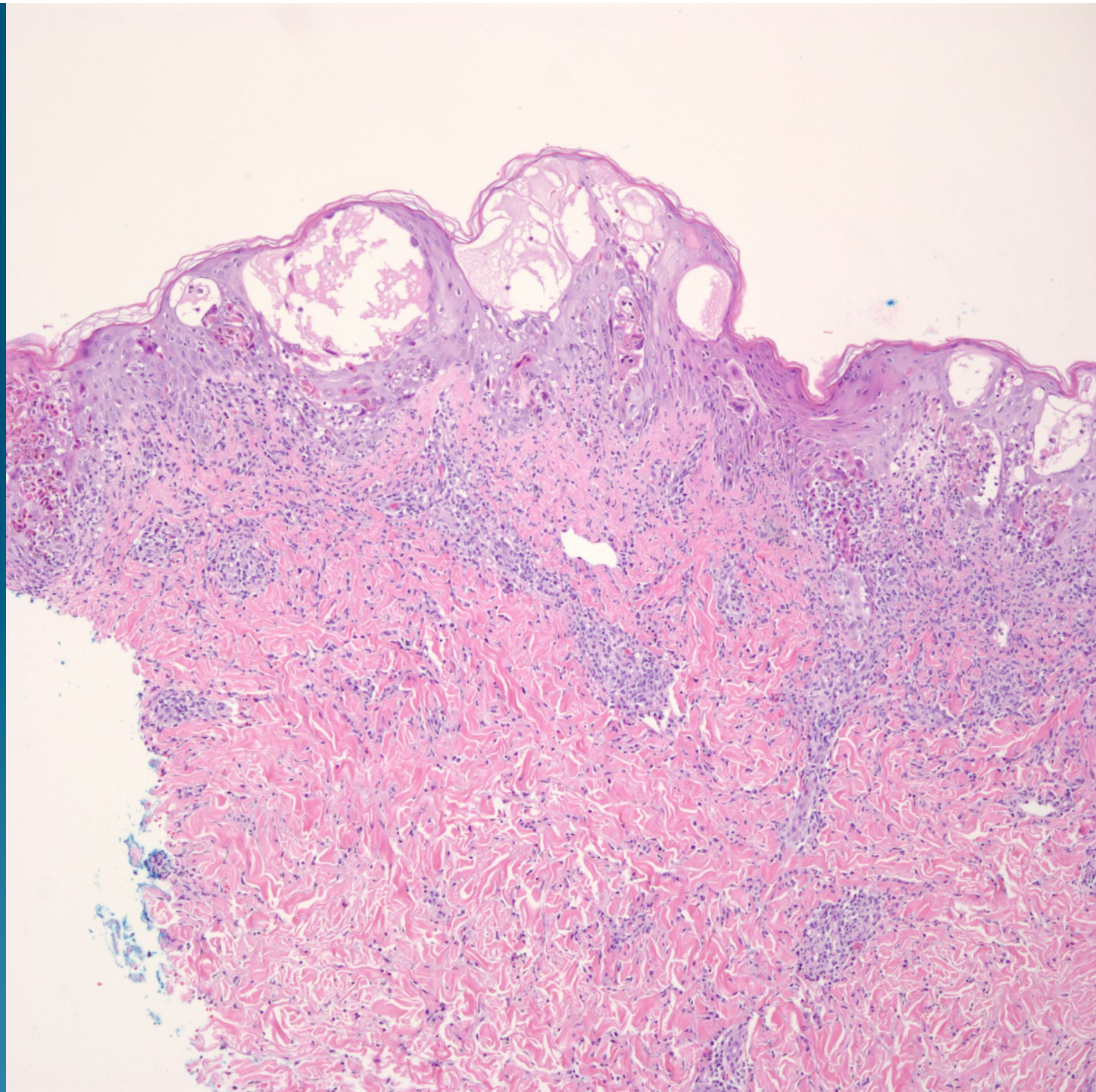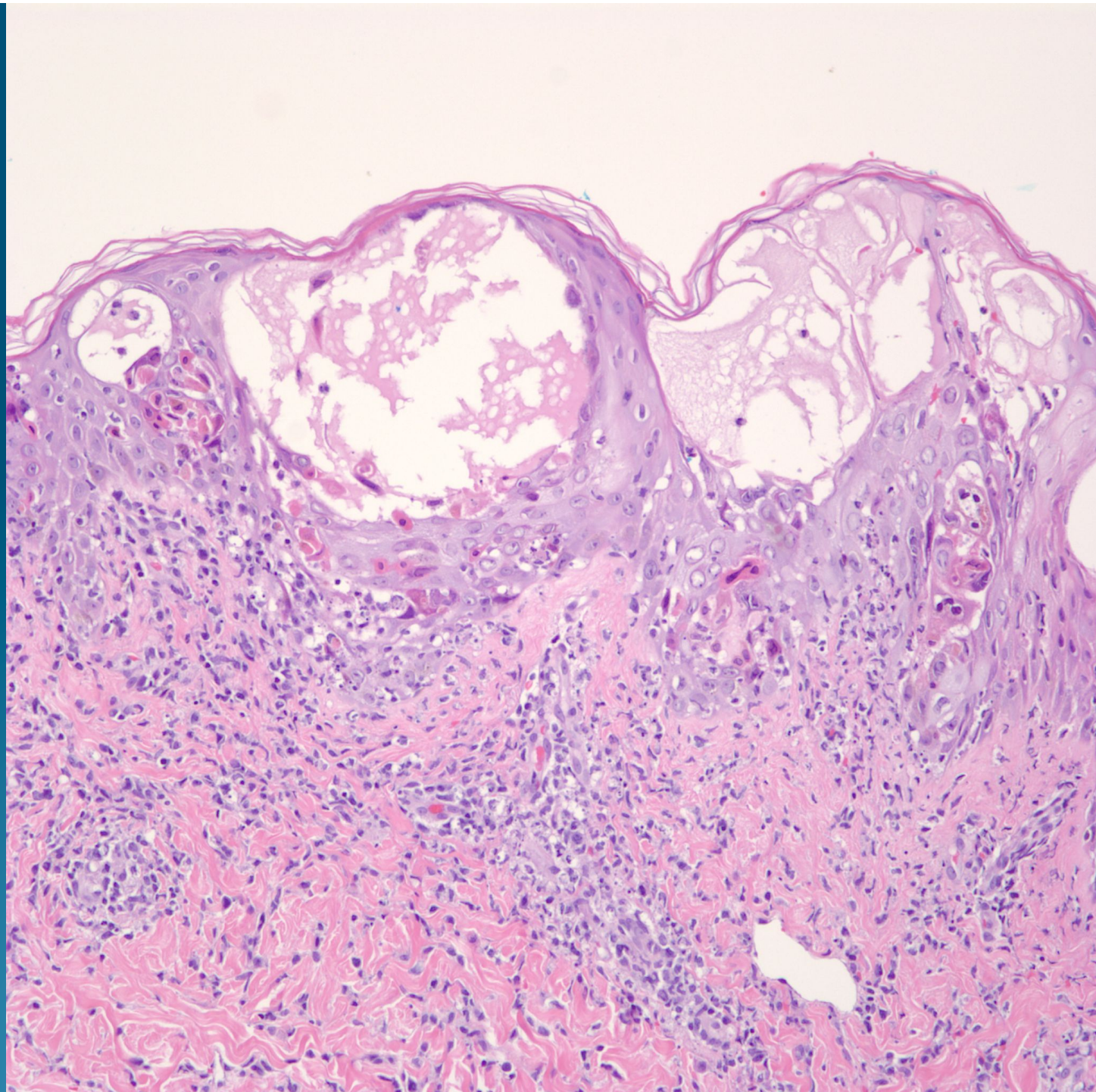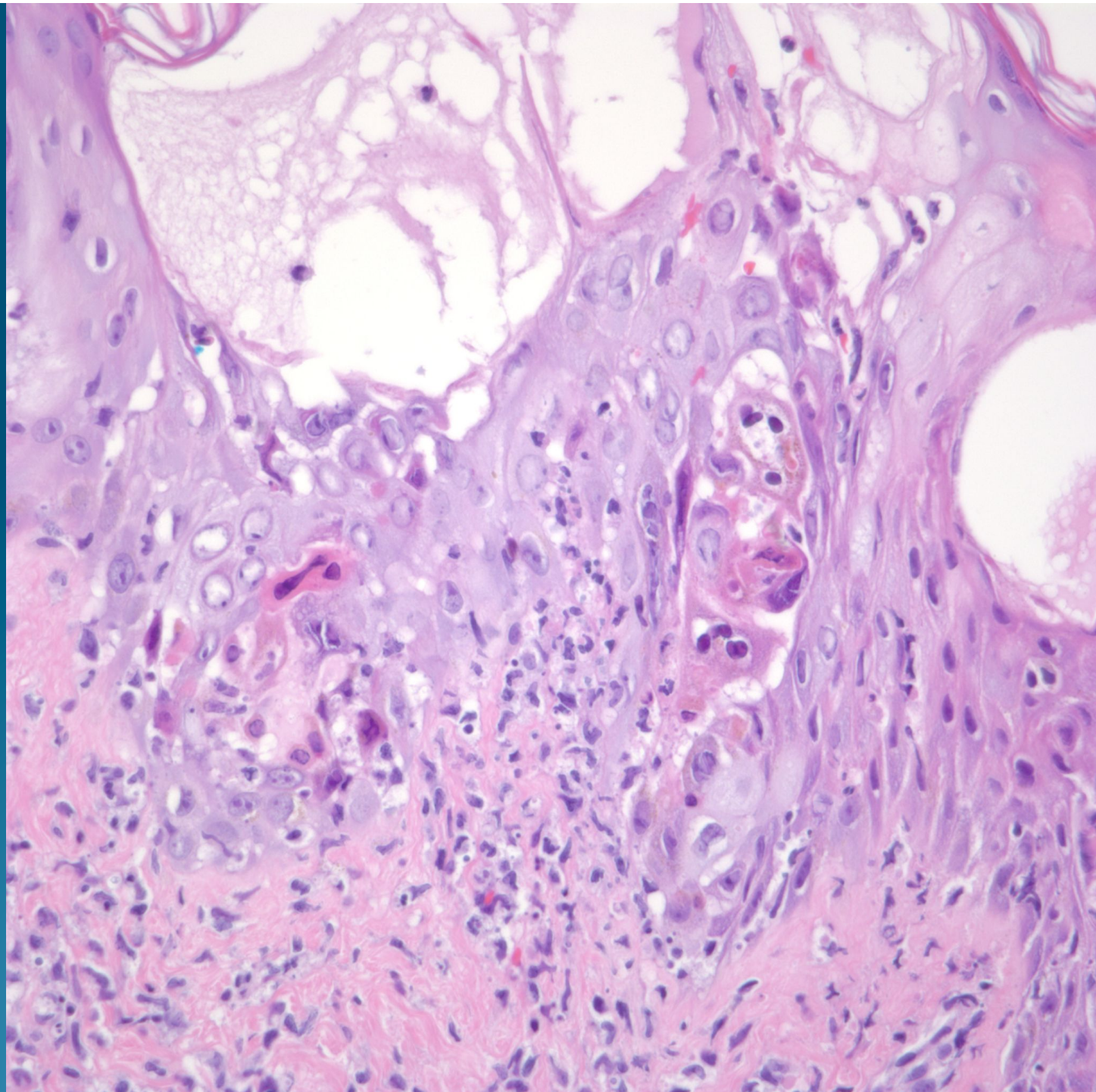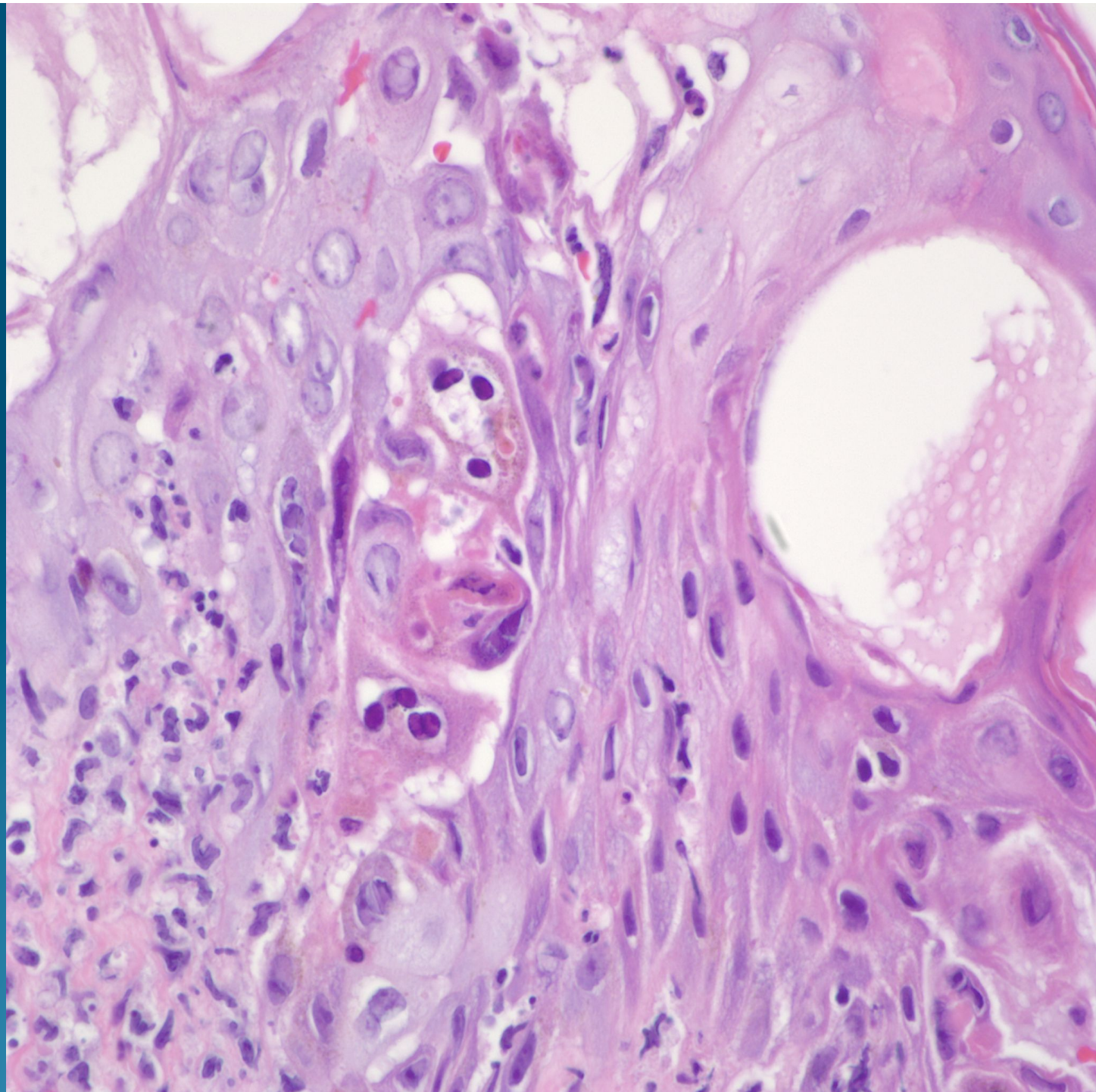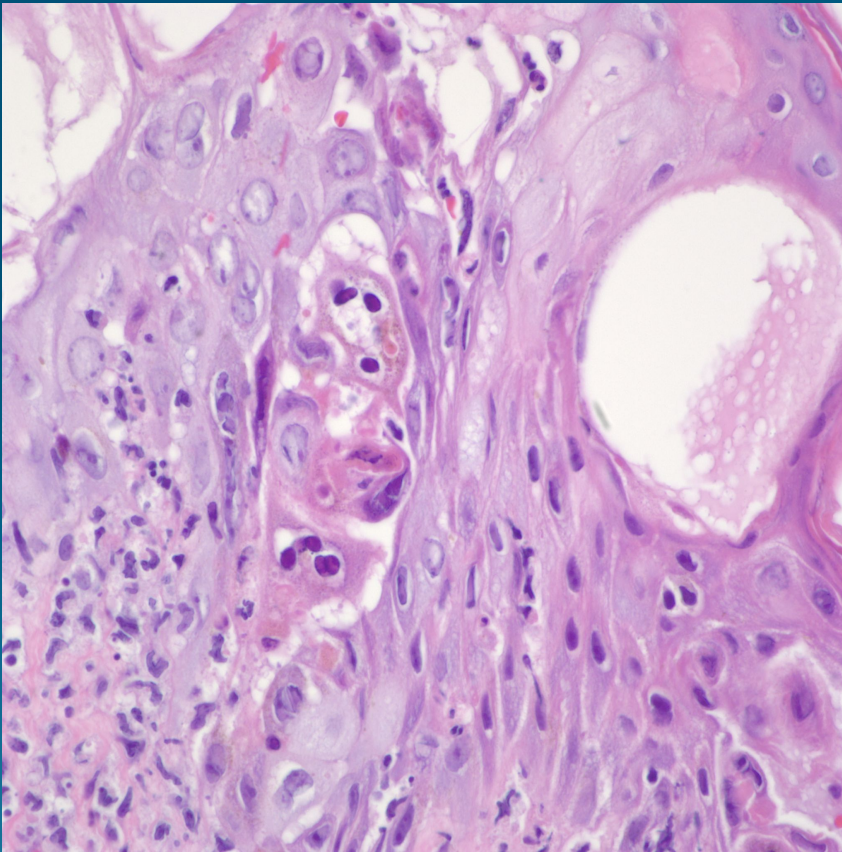


What is the best diagnosis?

- A. Orf
- B. Hand-Foot-Mouth Disease
- C. Molluscum contagiosum
- D. Myrmecia
- E. Varicella Zoster

Varicella Zoster

Pearls



- Intraepidermal vesicular dermatitis with acantholytic cells
- Nuclear chromatin margination with multinucleation
- Variable inflammation
- Histologically identical changes with Herpes Simplex virus infection, obtain IHC or cultures to rule out